

CASE REPORT

Congenital leukaemia after heavy abuse of permethrin during pregnancy

A Borkhardt, M Wilda, U Fuchs, L Gortner, I Reiss

Arch Dis Child Fetal Neonatal Ed 2003;**88**:F436–F437

A single case is described of congenital leukaemia with 11q23/MLL rearrangement in a preterm female newborn. Because of arachnophobia, the mother had heavily abused aerosolised permethrin, a widely used household insecticide. Permethrin is considered comparatively safe, but, in view of the mother's history, its potential to induce cleavage of the MLL gene in cell culture was tested. Incubation of the BV173 cell line with 50 μ M permethrin readily induced MLL cleavage.

Congenital leukaemia is a rare disease which affects about one child in 200 000–250 000 live births a year. In spite of its rarity, congenital leukaemia has stimulated much interest because of the opportunity to learn more about the underlying causes of in utero leukaemogenesis. There are many risk factors that may increase the chance of early induction of a leukaemic phenotype—for example, parental exposure to occupational and environmental toxins, use of tobacco, marijuana, alcohol, and other toxins.¹ Congenital and infant leukaemia are often associated with rearrangements of the MLL gene at chromosome 11q23.² Several substances have been examined for their potential to cross the placental barrier and to induce such a chromosomal break at 11q23/MLL.^{3,4}

Here we extend the list of drugs capable of cleaving the MLL gene, at least when cells are exposed in culture. Together with a rather unusual case history, our experimental data shed some light on the generation of congenital leukaemia and may help to prevent some of the fatal cases of this disease.

CASE REPORT

A 27 year old healthy woman was admitted to the gynaecology department because of premature labour. She was in the 35th week of her first pregnancy. Prenatal check ups had been normal. As the cardiotocogram showed no fetal heart rhythm, an emergency caesarean section was planned. However, six minutes later, the woman spontaneously gave birth to a premature infant weighing 2300 g and showing no vital signs but a striking livid colour of the skin. Primary cardiopulmonary resuscitation was started immediately with endotracheal intubation, chest compression, and repetitive administration of adrenaline. However, the Apgar score remained 0 after five and 10 minutes. The paediatric emergency team arrived 10 minutes later and continued to perform cardiopulmonary resuscitation. A central line was achieved by catheterisation of the umbilical vein. At 25 minutes post partum, a stable circulation was established, with a heart rate of 140 beats/min. A physical examination showed hepatomegaly of 5 cm below costal margin and nodular livid infiltrations of the skin (fig 1A).

Apart from normal anatomy of the heart, the ultrasound showed substantial pulmonary hypertension combined with second to third degree insufficiency of the tricuspid valve. Besides hepatomegaly, a bilateral intracranial haemorrhage

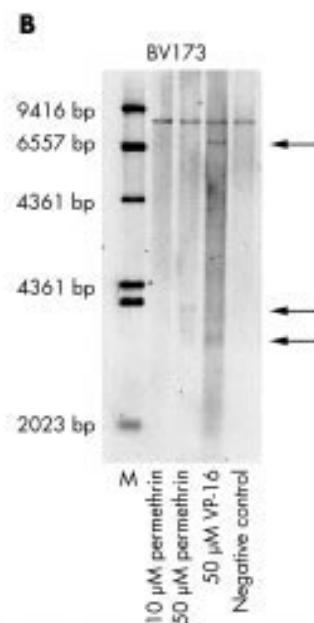
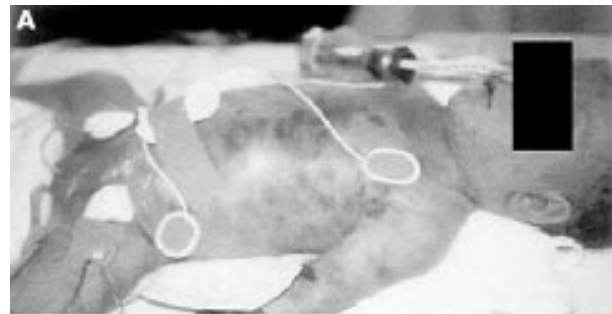


Figure 1 (A) The patient at 2 hours of age. Note the leukaemic skin infiltration ("blueberry spots"). (B) Southern blot showing an MLL rearrangement in the BV173 cell line incubated with 50 μ M permethrin for six hours. VP16 induced MLL cleavage was used as a control.

was found. For sufficient oxygenation and carbon dioxide removal, high frequency ventilation was needed with 10 Hz, $F_{I_{O_2}} = 1$, and a mean airway pressure of 13 cm H_2O . The initial white blood cell count was 400 000/ μ l with an excess of myeloid blast cells. Examination of the bone marrow confirmed the diagnosis of a congenital acute myeloid leukaemia, with 95% blast cells of myelomonocytic morphology (FAB-M5). A complete blood exchange was performed, which reduced the white blood cell count to 56 000/ μ l and resulted in an improvement in oxygenation and ventilation. Twelve hours later the white blood cell count had increased again, to

125 000/ μ l. Extracorporeal membrane oxygenation was considered but eventually rejected because of the progressive intracranial haemorrhage involving a large area of the parenchyma. The infant died 48 hours after birth from multiorgan failure. Apart from the severe brain damage already diagnosed by ultrasound, the autopsy showed diffuse infiltration of lungs, liver, spleen, and cutis.

CELL CULTURE EXPERIMENTS: INDUCTION OF MLL REARRANGEMENTS BY PERMETHRIN

The experimental assay was performed exactly as described by Strick *et al.*,³ who analysed a wide range of natural substances in food and dietary supplements for their ability to induce site specific cleavage within the MLL gene.

RESULTS AND DISCUSSION

Cytogenetic analysis of the bone marrow aspirate showed the presence of a translocation t(11;19)(q23;p13) in all metaphases analysed. Furthermore, we showed a rearrangement of the MLL oncogene at chromosome 11q23 by Southern blotting. Routine immunophenotyping showed expression of CD15, CD33, CD 65s, and MPO (data not shown). In previous studies, the monoclonal antibody 7.1 emerged as a valuable immunophenotypic tool for the detection of leukaemic cells, with NG2 antigen expression which correlates strongly with MLL rearrangements in infants.^{5,6} In our case, however, staining with this monoclonal antibody remained negative, which prevented us from carrying out further cell sorting experiments.

The mother had apparently suffered from arachnophobia since early childhood. Two years before her pregnancy she began to overuse aerosolised permethrin. Since then, she had lived alone. People avoided visiting her because of the penetrating odour in her house. Permethrin is a widely used household insecticide providing protection from the malaria vector *Anopheles*.^{7,8} It is also known to be an efficacious drug against scabies and the head louse *Pediculus capitis*.^{9,10} Compared with other drugs, it is considered safe and its topical use is recommended even for neonates with scabies.¹¹ However, it has been linked to the generation of both chromosomal aberrations in bone marrow cells of mice and DNA lesions in human lymphocytes.¹²⁻¹⁴ We therefore hypothesised that permethrin crossed the placenta of the pregnant woman and affected the haematopoietic precursor cells in the developing fetus, resulting in leukaemogenesis. We therefore tried to generate the rearrangements within the MLL oncogene in vitro by exposing BV173 cells to 50 μ M permethrin. After 24 hours of exposure, the permethrin treated BV173 cells showed a clear MLL rearrangement, whereas the untreated cells showed the wild type MLL gene only (fig 1B). Therefore we strongly recommend great caution in the use of permethrin during pregnancy. Even if definitive conclusions cannot be drawn from a single isolated case, our data strongly suggest that permethrin may have severe side effects when fetal haematopoietic precursor cells are exposed in utero. In the same vein, a recent report from a multinational collaboration indicated that use of mosquitocidal drugs during pregnancy is significantly associated with infant leukaemia.⁴ It is especially noteworthy that the authors found this association only for the MLL rearranged cases and not for MLL

germline cases. This strongly argues against selection bias in their case-control study and supports the hypothesis that in utero exposure causes the MLL rearrangements.

Finally, the mother in our case was successfully treated for arachnophobia by psychotherapy. Two years later, she gave birth to a healthy term boy who had no clinical sign of leukaemia and who is still healthy at the age of 13 months.

ACKNOWLEDGEMENTS

Expert technical assistance from Claudia Keller and Stefanie Garkisch is gratefully acknowledged. We thank Jochen Harbott, Giessen, Germany for providing us with the cytogenetic data. Immunophenotypic data were kindly provided by W-D Ludwig, Robert Rössle Cancer Centre, Humboldt University, Berlin, Germany. The molecular studies were supported by the German Cancer Foundation (grant 10-1658-Bo2).

Authors' affiliations

A Borkhardt, M Wilda, U Fuchs, I Gortner, I Reiss, Children's University Hospital Giessen, Feulgenstr 12, 35392 Giessen, Germany

Correspondence to: Dr Borkhardt, Paediatric Haematology and Oncology, Feulgenstr 12, 35392 Giessen, Germany; arndt.borkhardt@paediat.med.uni-giessen.de

Accepted 6 October 2002

REFERENCES

- 1 Sande JE, Arceci RJ, Lampkin BC. Congenital and neonatal leukemia. *Semin Perinatal* 1999; **23**:274-85.
- 2 Ford AM, Ridge SA, Cabrera ME, *et al.* In utero rearrangements in the trithorax-related oncogene in infant leukaemias. *Nature* 1993; **363**:358-60.
- 3 Strick R, Strissel PL, Borgers S, *et al.* Dietary bioflavonoids induce cleavage in the MLL gene and may contribute to infant leukemia. *Proc Natl Acad Sci USA* 2000; **97**:4790-5.
- 4 Alexander FE, Patheal SL, Biondi A, *et al.* Transplacental chemical exposure and risk of infant leukemia with MLL gene fusion. *Cancer Res* 2001; **61**:2542-6.
- 5 Smith FO, Rauch C, Williams DE, *et al.* The human homologue of rat NG2, a chondroitin sulfate proteoglycan, is not expressed on the cell surface of normal hematopoietic cells but is expressed by acute myeloid leukemia blasts from poor-prognosis patients with abnormalities of chromosome band 11q23. *Blood* 1996; **87**:1123-33.
- 6 Behm FG, Smith FO, Raimondi SC, *et al.* Human homologue of the rat chondroitin sulfate proteoglycan, NG2, detected by monoclonal antibody 7.1, identifies childhood acute lymphoblastic leukemias with t(4;11)(q21;q23) or t(11;19)(q23;p13) and MLL gene rearrangements. *Blood* 1996; **87**:1134-9.
- 7 Rowland M, Durrani N, Hewitt S, *et al.* Permethrin-treated chaddars and top-sheets: appropriate technology for protection against malaria in Afghanistan and other complex emergencies. *Trans R Soc Trop Med Hyg* 1999; **93**:465-72.
- 8 Binka FN, Mensah OA, Mills A. The cost-effectiveness of permethrin impregnated bednets in preventing child mortality in Kassena-Nankana district of Northern Ghana. *Health Policy* 1997; **41**:229-39.
- 9 Blanshard ME, Schofield J. Scabies: a practical approach. *Prof Care Mother Child* 1999; **9**:15-16.
- 10 Dodd CS. Interventions for treating headlice. *Cochrane Database Syst Rev* 2000; CD001165.
- 11 Quarterman MJ, Leshner JL, Jr. Neonatal scabies treated with permethrin 5% cream. *Pediatr Dermatol* 1994; **11**:264-6.
- 12 Cantalamessa F. Acute toxicity of two pyrethroids, permethrin, and cypermethrin in neonatal and adult rats. *Arch Toxicol* 1993; **67**:510-13.
- 13 Barrueco C, Herrera A, Caballo C, *et al.* Induction of structural chromosome aberrations in human lymphocyte cultures and CHO cells by permethrin. *Teratog Carcinog Mutagen* 1994; **14**:31-8.
- 14 Santoni G, Cantalamessa F, Spreghini E, *et al.* Alterations of T cell distribution and functions in prenatally cypermethrin-exposed rats: possible involvement of catecholamines. *Toxicology* 1999; **138**:175-87.