

# Intraosseous lines in preterm and full term neonates

Helmut Ellemunter, Burkhart Simma, Rudolf Trawöger, Heiner Maurer

## Abstract

**Aim**—To evaluate the use of intraosseous lines for rapid vascular access in primary resuscitation of preterm and full term neonates.

**Methods**—Thirty intraosseous lines were placed in 27 newborns, in whom conventional venous access had failed.

**Results**—All the neonates survived the resuscitation procedure, with no long term side effects.

**Conclusion**—Intraosseous infusion is quick, safe, and effective in compromised neonates.

(Arch Dis Child Fetal Neonatal Ed 1999;80:F74-F75)

Keywords: intraosseous infusion lines; primary resuscitation

In primary resuscitation of neonates, drug treatment is rarely required except for shock, terminal apnoea, or cardiac arrest. Under these conditions, it is usually impossible to administer drugs through a peripheral vein, because insufficient perfusion would most probably cause it to collapse. The preferred route is the umbilical vein, but it can be dangerous to inject drugs directly into the umbilical vein. Two alternative routes are available: the intratracheal and the intraosseous.<sup>1</sup> This study focuses on the use of intraosseous lines in premature infants and compromised neonates during resuscitation within five hours of birth.

## Methods

Preterm and full term infants admitted to the neonatal intensive care unit at this hospital over a one year period were eligible for study. When other routine means of access had been

exhausted, intraosseous needles were inserted in neonates requiring immediate resuscitation. The following substances were infused: catecholamines, volume expanders, sodium bicarbonate (in cases with confirmed metabolic acidosis), calcium gluconate, analgesics, sedatives, muscle relaxants, glucose, blood products and antibiotics. Medication was given as a bolus and/or continuously by means of infusion pumps with varying flow rates.

We considered the following conditions as contraindications for the use of intraosseous lines, namely: osteogenesis imperfecta, osteopetrosis, ipsilateral fracture or repeated placement of lines in the same bone.

A bone marrow needle or an intraosseous infusion needle (Cook Critical Care, Bloomington, IN, USA) with an internal diameter of 18 G was used. The site of insertion was the medial plate of the proximal tibia 0.5–1.0 cm distal to the tibial tuberosity (fig 1).<sup>1</sup> The needle was inserted under aseptic conditions by a caudally—that is, distal to the epiphyseal plate—directed screwing action until the marrow cavity was entered. Correct placement was confirmed by aspiration of bone marrow.

The site of needle placement was monitored every 30 minutes. The intraosseous line was replaced with an intravenous one as soon as the condition of the child stabilised.

## Results

Thirty intraosseous lines were placed for fluid and drug administration in 27 (20 preterm and seven full term newborns with respiratory distress syndrome, perinatal asphyxia, or congenital cardiac malformation. Mean (SD) gestational age was 31.8 (5.3) weeks (range 25 to 41 weeks); mean birthweight was 1780 (1027)g (range 515 to 4050 g). Table 1 details the characteristics of the neonates who underwent resuscitation procedures. All but one required intubation and mechanical ventilation, irrespective of gestational age. The entire procedure took less than two minutes.

The needles were left in place for a maximum of 20 hours (range 30 minutes to 20 hours). All patients survived the initial resuscitation with intraosseous lines. The clinical response showed that intraosseous rehydration to correct hypotension, hypoperfusion, and hypoglycaemia was successful. In three patients, dislocation and malfunctioning of the bone marrow needle necessitated placement of a new intraosseous needle. One patient developed subcutaneous necrosis due to extravasation of the hypertonic glucose infusion; another sustained a haematoma during blood transfusion. No major complications were observed. There were no failed attempts.

Department of Paediatrics, Innsbruck University Hospital, Anichstrasse 35 6020 Innsbruck, Austria  
H Ellemunter  
B Simma  
R Trawöger  
H Maurer

Correspondence to: Dr Helmut Ellemunter.

Accepted 24 June 1998

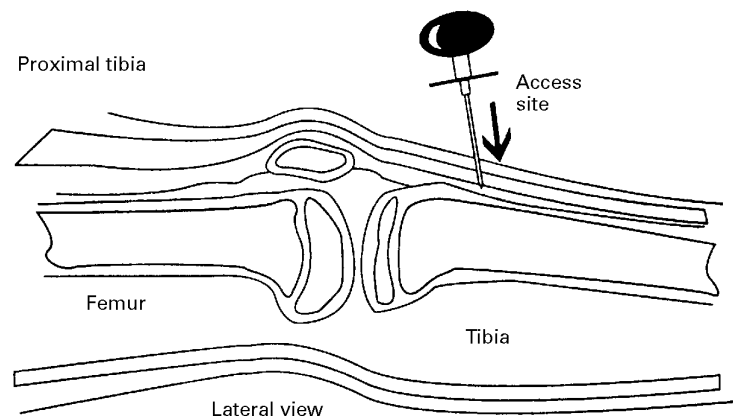


Figure 1 Appropriate placement of the intraosseous infusion needle on the medial surface, distal to tibial tuberosity.

Table 1 Clinical characteristics of study subjects

Subject No	Gestational age (weeks) *	Birthweight (g)	Sex	Apgar score (1-5-10 min)	Umbilical pH	Diagnosis	Duration of IO line (min)	Complications	Outcome
1	36	2170	F	0-2-4	ND	PA, twin	188	None	Survived
2	25	670	M	1-/-	7.23	AP, RDS	170	None	Died (day 14)
3	31	1560	M	ND	7.36	AP, RDS	246	None	Survived
4	471	3970	M	9-10-10	ND	Complex vitium cordis	45	None	Died (day 2)
5	25	515	F	1-1-	7.01	PA, RDA, AIS	I-200, II-405	Dislocation, haematoma	Died (day 2)
6	25	810	M	1-3-	ND	RDS, congenital malformation	91	None	Died (day 1)
7	31	1395	M	6-8-9	7.29	RDS	60	None	Survived
8	25	670	F	2-7-	ND	RDS, PDA	38	None	Died (day 18)
9	26	860	F	ND	7.35	RDS	310	None	Survived
10	34	2330	M	6-8-8	7.23	RDS, triplet	170	None	Survived
11	30	1500	M	0-3-	7.01	PA, hydrops fetalis, anaemia	75	None	Died (day 2)
12	29	820	F	ND	7.02	PA, RDS, triplet	320	None	Survived
13	29	740	M	1-3-	7.29	RDS, quadruplet	445	None	Died (day 2)
14	33	1960	F	1-	7.04	PA, RDS	470	None	Died (day 2)
15	35	1950	F	2-4-	7.30	RDS, PPH	130	None	Died (day 9)
16	30	1390	F	3-/-	ND	PA, RDS	100	None	Survived
17	30	1580	M	4-/-	7.32	PROM, RDS	90	None	Survived
18	31	1500	M	ND	7.19	RDS, AIS	400	Subcutaneous necrosis	Survived
19	40	4050	F	0-2-	6.90	PA, MAS	30	None	Survived
20	40	2650	F	ND	ND	RDS	845	None	Survived
21	36	3050	M	8-9-9	7.17	RDS, PPH	440	None	Died (day 2)
22	33	2440	F	6-7-	7.17	PA, RDS	I-51, II-435	Dislocation	Survived
23	40	3500	M	0-1-	6.86	PA	150	None	Died (day 6)
24	26	730	F	4-/-	7.20	RDS, AIS	I-1200, II-990	Dislocation	Died (day 2)
25	26	695	F	1-5-7	7.25	RDS, sepsis	189	None	Survived
26	33	2270	M	9-10-10	7.38	PROM, RDS, valvular PS	120	None	Survived
27	40	2290	M	8-8-5	7.23	RDS, pneumothorax	95	None	Survived

\* Completed weeks; ND = not done; IO = intraosseous; RDS = respiratory distress syndrome; PA = perinatal asphyxia; AP = abruptio placentae; PROM = premature rupture of membrane; AIS = amniotic infection syndrome; PDA = patent ductus arteriosus; PS = pulmonary stenosis; PPH = persistent pulmonary hypertension; MAS = meconium aspiration syndrome.

Twelve of the infants died later because of underlying disease (table 1). In long term follow up, no adverse effects from the use of intraosseous needles on limb growth were seen in any of the survivors (n=15).

### Discussion

Intraosseous lines have been used for the resuscitation of infants since 1943.<sup>2</sup> Intraosseous infusions have been applied successfully, particularly in critically ill infants.<sup>3</sup> However, little is known about the use of intraosseous needles in neonates and premature infants.<sup>4,5</sup> We have successfully used intraosseous lines in a large number of mainly preterm infants.

As neonates have a highly vascular and cellular marrow, drugs and fluids can be effectively administered through the marrow cavity. There are no pharmacokinetic differences between intraosseous and intravenous lines. Like peripheral blood, bone marrow aspirates after intraosseous infusion can be screened and typed accurately and reliably.

Known complications associated with the use of intraosseous needles in infants are osteomyelitis, skin infection, skin necrosis, subcutaneous abscess, fat embolism, fractures, compartment syndrome<sup>6</sup> due to prolonged intraosseous infusion and extravasation due to incomplete penetration of the cortex, penetration of the needle through a previous puncture site, or through the posterior aspect of the cor-

tex, and leakage through the foramina of the nutrient vessels. The complication rate in our study was low, although most newborn infants investigated were premature. Consistent with previous reports, no long term adverse effects on bone growth were seen in our patients.

In compromised neonates in whom intravenous access is impossible, immediate vascular access can be safely and rapidly established through intraosseous lines. However, they must be replaced with intravenous lines as soon as the infant stabilises. Various substances can be infused, at varying flow rates, either continuously or as a bolus. We suggest that the emergency set in every delivery room and neonatal intensive care unit be equipped with intraosseous needles. Training on an anatomical puppet (Resusci Baby, Laerdal Medical, Gräfelting, Germany) and experience are indispensable for safe application.

- 1 Advanced Life Support Group. Resuscitation of the newborn, Practical Procedures-circulation. In: *Textbook of Advanced Paediatric Life Support, The Practical Approach*. London: BMJ Publishing Group, 2nd edn, 1997:55-61, 197-208.
- 2 Heinild S, Søndergaard T, Tudvad F. Bone marrow infusions in childhood: experiences from a thousand infusions. *J Pediatr* 1947;30:400-11.
- 3 Fiser DH. Intraosseous infusion. *N Engl J Med* 1990;322:1579-81.
- 4 Ryder IG, Munro HM, Doull IJ. Intraosseous infusion for resuscitation. *Arch Dis Child* 1991;66:1442-3.
- 5 Kelsall AW. Resuscitation with intraosseous lines in neonatal units. *Arch Dis Child* 1993;68:324-5.
- 6 Vidal R, Kisson N, Gayle M. Compartment syndrome following intraosseous infusion. *Pediatrics* 1993;91:1201-2.