



Editor's choice  
Scan to access more  
free content

# Impact of retinopathy of prematurity on ocular structures and visual functions

Alistair Fielder,<sup>1</sup> Hannah Blencowe,<sup>2</sup> Anna O'Connor,<sup>3</sup> Clare Gilbert<sup>4</sup>

<sup>1</sup>Division of Optometry & Visual Science, City University, London, UK

<sup>2</sup>Faculty of Epidemiology and Population Health, London School of Hygiene and Tropical Medicine, London, UK

<sup>3</sup>Directorate of Orthoptics and Vision Science, University of Liverpool, Liverpool, UK

<sup>4</sup>Department of Clinical Research, International Centre for Eye Health, London School of Hygiene & Tropical Medicine, London, UK

## Correspondence to

Professor Alistair Fielder, Division of Optometry & Visual Science, City University, Northampton Square, London EC1 V 0HB, UK; [a.fielder@city.ac.uk](mailto:a.fielder@city.ac.uk)

Received 22 July 2014

Revised 23 September 2014

Accepted 4 October 2014

Published Online First

21 October 2014

## ABSTRACT

The preterm baby may develop ophthalmic sequelae which can be due to prematurity per se, due to retinopathy of prematurity (ROP) or due to neurological damage. Focusing on the former two, we discuss how in high-income countries the risk of sight-threatening ROP is largely confined to babies <1000 g birth weight (BW), whereas in low-income or middle-income countries babies exceeding 2500 g BW can be blinded. The effects of prematurity and ROP are presented as regional and global estimates of acute-phase ROP and the consequent mild/moderate and severe visual impairment. We discuss sequelae and how they affect the eye and its shape, strabismus and finally consider their impact on visual functions, including visual acuity, the visual field, colour vision and contrast sensitivity.

## INTRODUCTION

Retinopathy of prematurity (ROP) is a well-known complication of preterm birth. It is defined as a vision-threatening disease associated with abnormal retinal vascular development at the boundary of the vascularised and avascular peripheral retina. ROP has a clearly described natural history: the timing of its onset and progression being largely determined by postmenstrual age, which is rather consistent across ethnic groups and settings, with more mature infants having an earlier age at onset and a more contracted course to resolution or progression than more immature babies. In this article, we will frequently refer to mild and severe (acute) ROP with clinical findings described according to the International Classification of ROP revisited (box 1).<sup>1</sup> The term 'severe ROP' signifies ROP associated with clinically important sequelae, which include Stage 3 ROP, 'threshold'<sup>2</sup> and now Type I ROP<sup>3</sup>; the last two mentioned being the previous and current indications for treatment (box 2). All three terms are used in the literature to denote severe disease and while there are milder outliers in lesser degrees of Stage 3 ROP, these three categories include all sight-threatening diseases. Mild disease includes all Stage 1 ROP and Stage 2 ROP and nowadays all ROP not meeting Type I criteria. These stages usually resolve spontaneously sometimes after only a fleeting appearance.

The more severe degrees of ROP<sup>1 4</sup> can have varying degrees of impact on long-term visual function, including blindness. In order of severity, these are distortion and displacement of the macula, stretching and folding of the retina into a fold and retinal detachment which may be partial or total. Fibrous vitreous membranes can develop just behind the lens reminding us of the old term retrolental fibroplasia. In this situation, the eye is likely

to be slightly smaller than normal, leading to disruption of structures at the front of the eye which can be associated with inflammation (uveitis), cataract and glaucoma.<sup>5</sup> Finally, eyes with end-stage ROP may shrink (phthisis bulbi).

In this paper, we present and discuss the findings of a recent systematic review<sup>6</sup> in which the annual incidence of any degree of ROP was estimated as well as the incidence of visual loss from ROP in high-income, middle-income and low-income countries. However, ROP can have widespread impact on the structure and function of the eye, including refractive errors, and can increase the risk of abnormalities of ocular alignment (strabismus) and these topics are also discussed. It must be remembered that preterm infants are also at risk of other causes of visual loss from optic atrophy, and cerebral visual impairment (CVI) secondary to white matter injury. Some children born preterm have problems with visual perception. These topics are only briefly alluded to in this paper.

## WHO IS AFFECTED

### Risk factors

Which baby develops ROP, and the visual outcome, is greatly influenced by the standard of neonatal care received. In countries where high-quality neonatal care is available, events such as hyperoxia, hypoxia, hypercarbia, blood transfusions, hyperglycaemia and sepsis can all contribute to the development of ROP, but by far the greatest predictors are indices of immaturity—low gestational age (GA) and low birth weight (BW).<sup>7</sup> In countries with high-quality neonatal care, sight-threatening ROP is largely confined to babies with BW <1000 g and is very uncommon in babies >1250 g. In settings where the quality of neonatal care is more variable, the population of babies who develop severe ROP differs, with larger, more mature babies also being affected; indeed, severe ROP is being reported in babies over 34 weeks GA with BWs exceeding 2500 g.<sup>8 9</sup> This is largely due to prolonged, injudicious use of supplemental oxygen, frequently not blended or adequately monitored, which predominates over all other risk factors. However, many factors compound and contribute. These include—depending on the standard of care—all the aforementioned, suboptimal management of labour, poor nutrition and the absence of pain management.<sup>10</sup>

### ROP screening and treatment

The available evidence suggests that >50% babies with BW <1000 g develop some degree of acute ROP.<sup>11</sup> A recent systematic review and meta-analysis estimated that in 2010 around 184 700 babies developed any ROP worldwide with 53 500 of

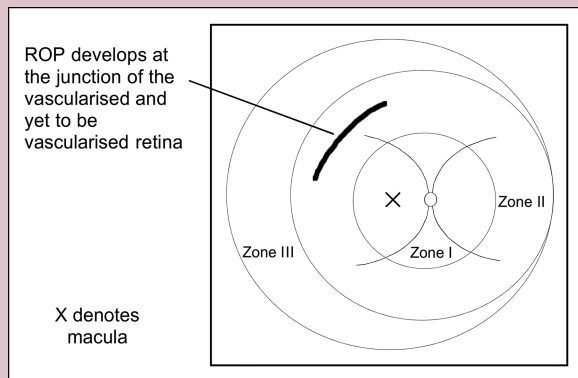


CrossMark

**To cite:** Fielder A, Blencowe H, O'Connor A, et al. *Arch Dis Child Fetal Neonatal Ed* 2015;**100**:F179–F184.

## Box 1 Describing acute-phase ROP (abbreviated)

Retinopathy of prematurity (ROP) is described by four major parameters according to the International Classification of ROP first devised in 1984 and revised in 2005.<sup>1</sup>



Acute ROP develops at the growing tips of the developing retinal blood vessels

1. Severity by stage (1–5)

Stages 1 and 2: demarcation line and ridge, respectively. Stage 3: ridge with extraretinal fibrovascular proliferation and carries a significant risk of adverse visual outcome. Stages 4 and 5 represent partial and total retinal detachment, respectively, and result in severe permanent visual impairment.

Aggressive posterior ROP (AP-ROP): described in 2005—an aggressive ROP type which does not progress through Stages 1–5 above but with very prominent plus disease.

2. Extent of the disease around the circumference of the globe Recorded in 'clock hours'.

3. Location of ROP along the antero-posterior meridian Retinal blood vessels grow progressively from Zone 1 to Zone 3, thus the stage of vascularisation is an indicator of maturity. Broadly, zone reflects maturity so ROP in Zone 3 is relatively mild and does not lead to severe disability.

4. Plus disease

Engorgement and tortuosity of the retinal blood vessels near the optic disc. Plus is a powerful indicator of ROP activity.

these developing Type I disease (table 1).<sup>6</sup> The majority (77%) of these in babies were in low-income and middle-income settings, with 27 000 (15%) being only moderately preterm (born at >32 weeks gestation). These are likely to be underestimates as the study focused on babies receiving neonatal intensive care as data were not available for babies in lower level facilities who may also receive poorly monitored supplemental oxygen.

In a small proportion of babies, ROP does not resolve but progresses to become severe, requiring treatment (box 2). Laser is currently the preferred modality.<sup>3</sup> Antivascular endothelial growth factor agents (ranibizumab or bevacizumab), despite a paucity of clinical research evidence, are being increasingly used, either as a primary treatment or as a rescue therapy after laser failure. However, the ocular and systemic safety and long-term efficacy of these agents are not yet known.<sup>12</sup> A high proportion of eyes with untreated severe ROP (approximately 60%) and a proportion of treated eyes can develop scarring and distortion of the retina, or retinal detachment, with irreversible

## Box 2 ROP treatment indications

Following the Multicenter Trial of Cryotherapy for Retinopathy of Prematurity in 1988,<sup>2</sup> the criterion for treatment was 'Threshold' retinopathy of prematurity (ROP). This is THE rather than A threshold as the term threshold has a specific meaning in the ROP field. Threshold ROP is defined as the stage at which the risk of blindness if untreated is estimated to be 50%. Between 1988 and 2003, the indication for treatment was

Threshold ROP:

*At least 5 continuous or 8 cumulative clock hours of Stage 3 ROP*

*In Zones I or II, and in the presence of plus disease.*

In 2003, Threshold was superseded by the revised recommendations for treatment proposed by the Early Treatment for Retinopathy of Prematurity (ETROP) Cooperative Group.<sup>3</sup> These criteria are referred to as pre threshold, Type I ROP, include threshold as defined above.

ETROP Recommendations:

Type I ROP

*Zone I any stage of ROP with plus disease and Stage 3 without plus disease*

*Zone II Stage 2 or 3 with plus disease.*

vision loss. The role of vitrectomy for the management of Stages 4 and 5 is highly controversial, relating more to patterns of clinical practice than the state of the eye. Some eyes with Stage 4 have limited vision following surgery; the results for Stage 5 are very poor.<sup>13</sup> Screening programmes are designed to detect those babies most at risk of progressing to sight-threatening disease. In the UK, for instance, it is recommended that all babies <31 weeks GA or <1251 g BW must be screened, and to catch the important outliers, babies ≥31 and <32 weeks GA or ≥1251 to <1501 g BW should also be screened.<sup>14</sup> In low-income or middle-income countries, there is a body of evidence that bigger, more mature babies also develop severe ROP, and in many of these countries the screening criteria are much wider.<sup>9</sup>

In countries and neonatal units where screening is undertaken, most babies with severe disease are treated. Despite this, around 12% of all babies with severe ROP will be visually impaired, with 5% being severely impaired. In low-income and middle-income settings, the provision of screening and treatment, and consequently visual outcomes, are much more variable. Middle-income countries currently have the largest estimated incidence accounting for three-quarters of all cases of ROP worldwide (table 1). Access to screening and treatment for ROP has lagged behind the development of neonatal intensive care unit (NICU) care, with only an estimated 40% of intensive care neonatal units in middle-income settings having ROP programmes. Much higher rates of visual impairment are therefore seen in these settings compared with high-income settings, with over 80% of visual impairment occurring in middle-income countries (table 1). Access to neonatal intensive care is still very limited in the predominantly low-income settings of South Asia and sub-Saharan Africa, and consequently few babies survive neonatal intensive care to develop ROP (13% of cases of ROP worldwide are from these regions compared with 59% of preterm births).<sup>6</sup>

**Table 1** Regional and global estimates of the annual incidence of retinopathy of prematurity (ROP), by severity, the number treated and the annual incidence of visual loss, by severity (from Blencowe)<sup>6</sup>

	High income	Middle income	Low income	Total*
Number with any ROP	41 400	139 000	4300	184 700
% of global total	22%	75%	2%	100%
Number with severe ROP	8700	43 400	1400	53 500
Phenotype of babies with severe ROP	Most <1250 g; all <1500 g	Wide heterogeneity with babies affected up to <~2500 g and <~34 weeks		
Number treated for severe ROP	6700	15 700	300	22 700
% of cases of severe ROP treated	79%	38%	21%	
Number with mild/moderate visual impairment from ROP	2900	9200	200	12 300
Number with severe visual impairment or blind from ROP	2600	16 900	600	20 000
Total with visual loss	5400	26 100	800	32 300
% of total burden of ROP-associated visual loss	17%	81%	2%	100%

Source: data based on reanalysis of Blencowe *et al* by WHO income groupings.<sup>6</sup>\*Numbers may not sum due to rounding.

### IMPACT OF ROP ON OCULAR STRUCTURE AND FUNCTION

Very preterm babies are more likely to develop sequelae other than those attributable to ROP compared with more mature preterm babies. The former have gestational periods that might have been shortened by up to 40%, meaning that other aspects of the visual system are also more immature at birth and vulnerable to perturbation. Extremely preterm babies are also likely to develop other comorbidities such as respiratory distress syndrome, sepsis, bronchopulmonary dysplasia and, of particular relevance to the visual system, white matter injury.<sup>15</sup>

Following the natural or induced regression of acute-phase ROP, a wide range of changes affecting the retina and the retinal vasculature may result.<sup>1-4</sup> How extensive these residuals are depends of the severity of the acute process. Mild sequelae have not attracted great interest until now, partly because they are difficult to visualise in detail in the older baby and young child, but also because they have less impact on visual function.

The following retinal sequelae of severe acute ROP do not usually have an impact on visual function: persistence of retinal vessel tortuosity, peripheral pigmentary retinal changes and vascular anomalies. With increasing severity, vision is affected: the retina and its vessels are 'dragged' towards the site of previous acute ROP (usually temporally) as shown by straightening and narrowing of the angle between the major vessels arising from the optic disc (figure 1). Finally, the macula is distorted, the retina can be detached and fibrous membranes develop in the vitreous as mentioned in the Introduction section.

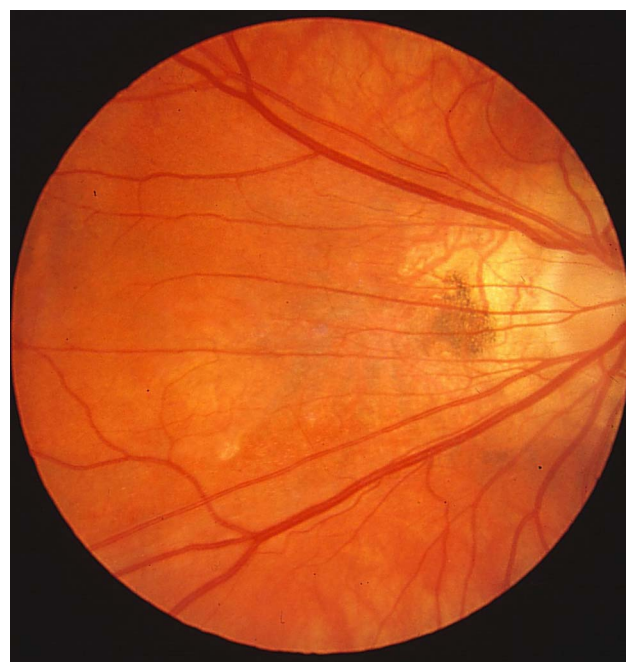Regression of severe acute-phase ROP, induced or not by treatment, is not necessarily the end of the story as there is an increased risk of retinal detachment later in life. For example, the 15-year follow-up of children recruited to the Multicenter Trial of Cryotherapy for Retinopathy of Prematurity reported the annual incidence of retinal detachment to be 0.35% in cryotherapy-treated eyes and 0.51% in untreated eyes.<sup>16</sup> Surgery for retinal detachment at this stage is important and of far greater benefit than vitrectomy for detachment during infancy (Stages 4 and 5). Insidious loss of function may also occur infrequently many decades later.<sup>17</sup>

### Effect of ROP on the eye and its shape

Emmetropisation is the process of refractive development whereby the ocular components grow in a coordinated fashion to create an eye without refractive error. This process, which is

fine-tuned by vision, is jeopardised in the preterm baby for two reasons: first, the effect of being born preterm and second, as a consequence of ROP.

Early exteriorisation due to preterm birth shortens the intra-uterine period and removes the fetus from a protective environment ideally suited to promote growth and provides the optimal level of stimulation. Unsurprisingly, the visual system of the preterm baby can be affected by removal from this *milieu* as well as by exposure to a very different biological and physical environment. Fledelius demonstrated over 30 years ago that the eyes of children born prematurely but who did not have ROP did not grow normally.<sup>18</sup> He showed that structures at the front of the eye, namely the cornea and lens, both of which play a vital role in focusing light onto the retina, were different:



**Figure 1** Straightening of the retinal vessels arising from the optic disc and narrowing of the angle between the major vessels. Mild dragging of the vessels to the left of the image, extending across the macula towards the temporal retinal periphery.



corneas of children born preterm are more curved, and the lens is thicker, both of which increase the focusing power of the eye, leading to short-sightedness (myopia). This myopia, which is not due to ROP, is of low degree and is referred to as 'myopia of prematurity'.<sup>18–21</sup> Studies have shown that all individuals born preterm are more prone than their full-term counterparts to all refractive errors—astigmatism (irregular curvature of the cornea which distorts vision), hypermetropia (long-sightedness) and anisometropia (different refractive state between the two eyes).<sup>19 20</sup>

While mild ROP does not contribute additionally to refractive state, following severe acute ROP refractive development is very different, as all of the aforementioned refractive errors occur, but to a greater degree.<sup>19 21 22</sup> and high myopia (>5 dioptres) only occurs following severe ROP. The prevalence of refractive errors varies across studies, as shown in table 2, being highest in the extremely low BW group (ie, BW <1000 g) and following treatment for severe ROP. Myopia attracts the most attention<sup>23</sup> as high degrees are not rare and even a small amount of myopia affects distance visual acuity which requires correction. In contrast, the impact of hypermetropia on visual performance is not linear and its correction is not clearly defined, although there is no doubt that higher degrees do need to be corrected.<sup>24</sup>

Long debated, it appears that myopia following severe ROP is related to the disease process itself and is not a complication of ROP treatment by either cryotherapy or laser. Myopia associated with severe ROP progresses during the first 6–9 months and to a lesser extent thereafter, becoming relatively stable by around 3 years of age. This is quite different from the mild myopia associated with prematurity which has a later onset and progresses in severity into the teens. It is possible that myopia is less following bevacizumab treatment compared with laser or cryotherapy, a potentially important finding which needs further study.

To summarise, refractive development is perturbed by preterm birth per se and ex-preterm children have an increased prevalence of all refractive errors, especially low myopia. Mild ROP does not contribute to the refractive state, over and above that which is attributable to preterm birth. Following severe ROP, there is an increase in all refractive errors, including myopia, and frequently high myopia.

## STRABISMUS

One of the visible signs of a disturbance in the normal process of visual development is the presence of strabismus (misalignment of the eyes) which can be due to loss of vision in one or both eyes, cranial nerve palsies and/or disorders of the higher visual pathways. Prevalence ranges from 16% to 22% in ex-preterm children,<sup>19 21 28 29</sup> which is substantially higher than among children born at term (1–3%). All studies report that strabismus is more prevalent in preterm children, but the findings in relation to ROP differ, one study reporting increase by ROP stage, not confirmed in another study. Recently, it was reported that 60% of children with Type I ROP had strabismus.<sup>30</sup> Some of the differences may be attributable to classification by clinical characteristics, not aetiology. Given the higher rates of neurological deficits in children with ROP and that neurological deficits due to white matter injury are associated with a high incidence of strabismus,<sup>28 31</sup> it is impossible to determine the direct impact of ROP alone. Strabismus per se can lead to loss of visual function from strabismic amblyopia and thus needs to be detected so that the child can be referred for treatment.

## VISUAL FUNCTIONS

Following preterm birth, there are three key factors that influence visual outcome, the presence of ROP or neurological comorbidities and preterm birth itself.

Table 1 clearly demonstrates the high rates of visual impairment following ROP and while the rates are lower with a higher rate of treated cases, treatment infrequently results in normal vision with 35%, 49% and 75% achieving 6/12 or better, 6/18 or better and 6/60 or better<sup>32</sup>—data not fully excluding CVI. That significant retinal damage resulting from severe ROP is clearly linked to long-term visual impairment, however, milder forms of ROP may also impact on visual outcome, but epidemiological studies have differed in their findings in this respect. This may be because mild ROP is transient and may therefore not be identified, falsely biasing conclusions. While it is not clear whether mild ROP affects vision, as preterm birth itself confers an additional risk for impaired visual function, not identifying all cases may be biasing the conclusions.

**Table 2** Refractive state following preterm birth with and without retinopathy of prematurity (ROP)

Study	BW/GA	ROP	Age	Refractive errors
EXPRESS <sup>25</sup>	<27 weeks	73.7% (20.4% treated)	30 months	25.6%—all
CRYO-ROP Study <sup>26</sup>	<1251 g	All reached threshold (82.5% bilateral)	3.5 years	Moderate myopia ( $\geq 2$ D to <6 D): ► Treated eyes 20.5% ► Untreated eyes 15.5% High myopia ( $\geq 6$ D): ► Treated eyes 37.7% ► Untreated eyes 27.2%
ETROP <sup>27</sup>	<1251 g	High-risk prethreshold	6 years	Astigmatism $\geq 52\%$ in all treated eyes High astigmatism $\geq 23\%$ in all treated eyes Myopia $\geq 65\%$ in all treated eyes High myopia $\geq 35\%$ in all treated eyes
ETROP <sup>23</sup>				
Larsson and Holmström <sup>20</sup>	<1501 g	39%	10 years	Moderate myopia 3.8% Moderate hypermetropia 4.2% Astigmatism 21%
O'Connor <i>et al</i> <sup>22</sup>	<1701 g	50%	10–12 years	Mild myopia 15.2% Moderate myopia 3.8% Moderate hypermetropia 6.6%

Refractive errors are defined (unless otherwise stated) as mild myopia <3.0 dioptre sphere, moderate  $\geq 3$  dioptre sphere, high myopia >5.0 dioptre sphere, moderate hypermetropia  $\geq 3.0$  dioptre sphere, astigmatism  $\geq 1.00$  dioptres and high astigmatism  $\geq 2.00$  dioptres.  
BW, birth weight; D, dioptre; GA, gestational age.

Comorbidities such as neurological disorders due to white matter injury can have a significant impact on a child's visual abilities. The resultant CVI is now the most common cause of visual impairment in children in the developed world. Differentiating the effects on vision of CVI and ROP can be difficult except when the retina is obviously disorganised. CVI encompasses a wide range of effects from blindness through to visual neglect and simultanagnosia (inability to process a crowded scene).<sup>33</sup> The latter may not be detected by routine clinical assessment such as visual acuity measurement, requiring specific questions to elicit difficulties in visual perception.

Of course, real life vision depends on more than visual acuity, and impaired visual function can occur in the presence of normal visual acuity. Other functions to consider include the visual field, colour vision and contrast sensitivity.

### Visual acuity

It has long been known that children who were born preterm, but did not have ROP, may have reduced visual acuity compared with children born at full term.<sup>18 34 35</sup> These deficits are subtle with acuity levels usually lying at the lower border of the normal range. The basis of these acuity deficits has hitherto been unknown, but recent advances in optical coherent tomography show that children born preterm can have subtle changes in the detailed anatomy of the central retina. However, these structural abnormalities do not correlate very well with function, which suggests that other processes are also involved.<sup>36</sup>

### The visual field

In the Multicenter Trial of Cryotherapy for Retinopathy of Prematurity, it was reported<sup>37</sup> that at the age of 10 years the visual field was constricted to a similar extent (ie, by 5° to 10°) whether or not the ROP had been treated by peripheral retinal ablation; this was subsequently confirmed by Larsson and co-workers.<sup>38</sup> Laser ablative treatment at the earlier stage of Type I prethreshold not only did not cause further constriction as feared, but counterintuitively resulted in slight preservation of the field compared with eyes treated at threshold.<sup>39</sup> The level of visual field constriction attributable to ROP does not have a major functional impact and driving is not precluded.

### Colour vision and contrast sensitivity

Subtle colour vision deficits have been described in association with preterm birth but are ROP independent.<sup>40</sup> Contrast sensitivity is an important visual function and may be adversely affected by preterm birth, neurological abnormalities and severe ROP.

While the clinical measures of visual function are made in isolation, they frequently coexist. The cumulative impact on functional ability is unknown, in particular in a group of children that may have other physical disabilities, and while normal visual acuity may not be a realistic goal, all treatments aim to maximise visual function.

### CONCLUSION

We have described the sequelae of ROP but differentiating the effects of preterm birth, ROP and neurological damage can be difficult and sometimes impossible. In general, being born early does affect the visual system and its functions, albeit to a relatively mild degree, and mild ROP does not (with one or two exceptions) contribute additionally to these deficits. There have been major advances in ROP treatment over the past three decades; however, severe ROP, even if treated, still results in a degree of visual disability, fortunately of lesser severity than

previously. Looking forward, the prevention of ROP through high-quality neonatal care, including the safe use of oxygen, is critical to improve visual outcomes in preterm infants worldwide.

**Competing interests** None.

**Provenance and peer review** Commissioned; externally peer reviewed.

### REFERENCES

- 1 An International Committee for the Classification of Retinopathy of Prematurity. The International Classification of Retinopathy of Prematurity revisited. *Arch Ophthalmol* 2005;123:991–9.
- 2 Cryotherapy for Retinopathy of Prematurity Cooperative Group. Multicenter trial of cryotherapy for retinopathy of prematurity: preliminary results. *Arch Ophthalmol* 1988;106:471–9.
- 3 Early Treatment for Retinopathy of Prematurity Cooperative Group. Revised indications for the treatment of retinopathy of prematurity. *Arch Ophthalmol* 2003;121:1684–96.
- 4 The International Committee for the Classification of the Late Stages of Retinopathy of Prematurity. An International Classification of Retinopathy of Prematurity. *Arch Ophthalmol* 1987;105:906–12.
- 5 Smith BT, Tasman WS. Retinopathy of prematurity: late complications in the baby boomer generation (1946–1964). *Trans Am Ophthalmol Soc* 2005;103:225–34.
- 6 Blencowe H, Lawn JE, Vazquez T, et al. Preterm-associated visual impairment and estimates of retinopathy of prematurity at regional and global levels for 2010. *Pediatr Res* 2013;74(Suppl 1):35–49.
- 7 Hellstrom A, Smith LE, Dammann O. Retinopathy of prematurity. *Lancet* 2013;382:1445–57.
- 8 Gilbert C, Fielder A, Gordillo L, et al; International NO-ROP Group. Characteristics of infants with severe retinopathy of prematurity in countries with low, moderate, and high levels of development: implications for screening programs. *Pediatrics* 2005;115:e518–25.
- 9 Wilson CM, Ellis AL, Fielder AR. The challenge of screening for retinopathy of prematurity. *Clin Perinatol* 2013;40:241–59.
- 10 Darlow BA, Gilbert CE, Quiroga AM. Setting up and improving retinopathy of prematurity programs: interaction of neonatology, nursing, and ophthalmology. *Clin Perinatol* 2013;40:215–27.
- 11 Zin A, Gole GA. Retinopathy of prematurity-incidence today. *Clin Perinatol* 2013;40:185–200.
- 12 Darlow BA, Ellis AL, Gilbert CE, et al. Are we there yet? Bevacizumab therapy for retinopathy of prematurity. *Arch Dis Child Fetal Neonatal Ed* 2013;98:F170–4.
- 13 Repka MX, Tung B, Good WV, et al. Outcome of eyes developing retinal detachment during the Early Treatment for Retinopathy of Prematurity study. *Arch Ophthalmol* 2011;129:1175–9.
- 14 Wilkinson AR, Haines L, Head K, et al. UK retinopathy of prematurity guideline. *Early Hum Dev* 2008;84:71–4. Guideline in full <http://www.rcpch.ac.uk>, <http://www.rcophth.ac.uk>.
- 15 Costeloe KL, Hennessy EM, Haider S, et al. Short term outcomes after extreme preterm birth in England: comparison of two birth cohorts in 1995 and 2006 (the EPICure studies). *BMJ* 2012;345:e7976.
- 16 Palmer EA, Hardy RJ, Dobson V, et al. 15-year outcomes following threshold retinopathy of prematurity: final results from the multicenter trial of cryotherapy for retinopathy of prematurity. *Arch Ophthalmol* 2005;123:311–18.
- 17 Fledelius HC, Jensen H. Late subsequent ocular morbidity in retinopathy of prematurity patients, with emphasis on visual loss caused by insidious 'involutive' pathology: an observational series. *Acta Ophthalmol* 2011;89:316–23.
- 18 Fledelius HC. Pre-term delivery and subsequent ocular development. A 7–10 year follow-up of children screened 1982–84 for ROP. 4) Oculometric—and other metric considerations. *Acta Ophthalmol* 1996;74:301–5.
- 19 O'Connor AR, Stephenson TJ, Johnson A, et al. Long term ophthalmic outcome of low birth weight children with and without retinopathy of prematurity. *Pediatrics* 2002;109:12–18.
- 20 Larsson E, Holmström G. A population-based study of the refractive outcome in 10-year-old preterm and full-term children. *Arch Ophthalmol* 2003;123:1430–36.
- 21 Holmström G, Larsson E. Outcome of retinopathy of prematurity. *Clin Perinatol* 2013;40:311–21.
- 22 O'Connor AR, Stephenson TJ, Johnson A, et al. Change of refractive state and eye size in children of birth weight less than 1701g. *Br J Ophthalmol* 2006;90:456–60.
- 23 Quinn GE, Dobson V, Davitt BV, et al. Progression of myopia and high myopia in the Early Treatment for Retinopathy of Prematurity study: findings at 4 to 6 years of age. *J AAPOS* 2013;17:124–8.
- 24 O'Connor AR. Hypermetropia in childhood: a review of research relating to clinical management. *Br J Orthopt J* 2008;5:15–21.
- 25 Holmström GE, Kallen K, Hellstrom A, et al. Ophthalmologic outcome at 30 months' corrected age of a prospective Swedish cohort of children born before 27

- weeks of gestation: the extremely preterm infants in sweden study. *JAMA Ophthalmol* 2014;132:182–9.
- 26 Quinn GE, Dobson V, Siatkowski R, *et al*; Cryotherapy for Retinopathy of Prematurity Cooperative Group. Does cryotherapy affect refractive error? Results from treated versus control eyes in the cryotherapy for retinopathy of prematurity trial. *Ophthalmology*. 2001;108:343–7.
  - 27 Davitt BV, Quinn GE, Wallace DK, *et al*. Astigmatism progression in the early treatment for retinopathy of prematurity study to 6 years of age. *Ophthalmology* 2011;118:2326–9.
  - 28 O'Connor AR, Stephenson TJ, Johnson A, *et al*. Strabismus in children of birth weight less than 1701g. *Arch Ophthalmol* 2002;120:767–73.
  - 29 Holmström G, Rydberg A, Larsson E. Prevalence and development of strabismus in 10-year-old premature children: a population-based study. *J Pediatr Ophthalmol Strabismus* 2006;43:346–52.
  - 30 VanderVeen DK, Bremer DL, Fellows RR, *et al*. Prevalence and course of strabismus through age 6 years in participants of the Early Treatment for Retinopathy of Prematurity randomized trial. *J AAPOS* 2011;15:536–40.
  - 31 Hellgren K, Aring E, Jacobson L, *et al*. Visuospatial skills, ocular alignment, and magnetic resonance imaging findings in very low birth weight adolescents. *J AAPOS* 2009;13:273–79.
  - 32 Good WV, Hardy RJ, Dobson V, *et al*. Final visual acuity results in the early treatment for retinopathy of prematurity study. *Arch Ophthalmol* 2010; 128:663–71.
  - 33 Macintyre-Béon C, Young D, Dutton GN, *et al*. Cerebral visual dysfunction in prematurely born children attending mainstream school. *Doc Ophthalmol*. 2013;127:89–102.
  - 34 O'Connor AR, Stephenson TJ, Johnson A, *et al*. Visual function in low birthweight children. *Br J Ophthalmol* 2004;88:1149–53.
  - 35 Fledelius HC. Ophthalmic changes from age of 10 to 18 years. A longitudinal study of sequels to low birth weight. II: Visual acuity. *Acta Ophthalmol* 1981;59 (Suppl):64–70.
  - 36 Wu WC, Lin RI, Shih CP, *et al*. Visual acuity, optical components, and macular abnormalities in patients with a history of retinopathy of prematurity. *Ophthalmology* 2012;119:1907–16.
  - 37 Quinn GE, Dobson V, Hardy RJ, *et al*. Visual fields measured with double-arc perimetry in eyes with threshold retinopathy of prematurity from the cryotherapy for retinopathy of prematurity trial. *Ophthalmology* 1996;103:1432–37.
  - 38 Larsson E, Martin L, Holmstrom G. Peripheral and central visual fields in 11-year-old children who had been born prematurely and at term. *J Pediatr Ophthalmol Strabismus* 2004;41:39–45.
  - 39 Quinn GE, Dobson V, Hardy RJ, *et al*. Visual field extent at 6 years of age in children who had high-risk prethreshold retinopathy of prematurity. *Arch Ophthalmol* 2011;129:127–32.
  - 40 Dobson V, Quinn GE, Abramov I, *et al*. Color vision measured with pseudoisochromatic plates at five-and-a-half years in eyes of children from the CRYO-ROP study. *Invest Ophthalmol Vis Sci* 1996;37:2467–74.